BIOMODULATORY EFFECTS OF LLLT ON BONE REGENERATION

Antonio L.B. Pinheiro[1], Marilia G. Oliveira[2], Pedro Paulo M. Martins[3], Luciana Maria Pedreira Ramalho[4], Marcos A. Matos de Oliveira[5], Aurelício Novaes Júnior and Renata Amadei Nicolau

[1] School of Dentistry, Department of Diagnostic and Therapeutics, Universidade Federal da Bahia, Salvador, BA, 40110-150,Brazil; [2] School of Dentistry, Post-Graduate Program on Oral and Maxillofacial Surgery, Pontifícia Universidade Católica do Rio Grande do Sul, Porto Alegre, RS, Brazil; [3]School of Dentistry, University of Pernambuco, Camaragibe, 50000-000,Brazil; [4]School of Dentistry, Laser Center, Universidade Federal da Bahia, Salvador, BA, 40110-150,Brazil; [5]Lecture, Institute of Research and Development (IP&D) Universidade Vale do Paraíba (UNIVAP) - São José dos Campos,SP, 12244-000, Brazil

Tissue healing is a complex process that involves local and systemic responses. The use of Low Level Laser Therapy (LLLT) for wound healing has been shown to be effective in modulating both local and systemic response. Usually the healing process of bone is slower than that of soft tissues. The effects of LLLT on bone are still controversial as previous reports show different results. This paper reports recent observations on the effect of LLLT on bone healing. The amount of newly formed bone after 830nm laser irradiation of surgical wounds created in the femur of rats was evaluated morphometricaly. Forty Wistar rats were divided into four groups: group A (12 sessions, 4.8J/cm^2 per session, 28 days); group C (three sessions, 4.8J/cm^2 per session, seven days). Groups B and D acted as non-irradiated controls. Forty eight hours after the surgery, the defects of the laser groups were irradiated transcutaneously with a CW 40mW 830nm diode laser, (f~1mm) with a total dose of 4.8J/cm^2. Irradiation was performed three times a week. Computerized morphometry showed a statistically significant difference between the areas of mineralized bone in groups C and D (p=0.017). There was no significant difference between groups A and B (28 days) (p=0.383). In a second investigation, we determined the effects of LLLT on bone healing after the insertion of implants. It is known that dental implants need four and six months period for fixation on the maxillae and on the mandible before receiving loading. Ten male and female dogs were divided into two groups of five animals that received the implant. Two animals of each group acted as controls. The animals were sacrificed 45 and 60 days after surgery. The animals were irradiated three times a week for two weeks in a contact mode with a CW 40mW 830nm diode laser, (f ~1mm) with a total dose per session of 4.8J/cm^2 and a dose per point of 1.2J/cm^2. The results of the SEM study showed better bone healing after irradiation with the 830nm diode laser. These findings suggest that, under the experimental conditions of the investigation, the use of LLLT at 830nm significantly improves bone healing at early stages. It is concluded that LLLT may increase bone repair at early stages of healing.

KEY WORDS: Bone Healing, Histomorphometry, Laser Therapy, Dental Implants.

Introduction

Tissue healing is a complex process that involves local and systemic responses. The process of wound healing involves several types of cells; enzymes; growth factors and other substances. The use of LLLT (Low Level Laser Therapy) for wound healing has been shown to be effective in modulating both local and systemic response. In soft tissues it has been shown that, depending on the wavelength, dose, and local condition, LLLT has anti-inflammatory effect, reduces pain; quickens cell proliferation [11,14-16,24] and consequently promotes the healing process. Bone healing differs from that of soft tissues because of its morphology and composition. Usually the healing process of bone is slower than that of soft tissues [17]. The natural course of bone healing comprises of consecutive phases, which differs according to the type and intensity of trauma and the extent of damage to the bone. Traumatic injuries are major sources of bone fractures. These injuries may occur in several situations and usually impair the patients´ abilities to perform their normal daily activities, bringing about problems for both the patient and employers given reduced work capacity over several weeks. Confining civilian or military activities such as petroleum platform work, space trips and submarine work, further hinder the management of skeletal injuries. It is known that lack of gravity and extremely high pressures can further impair the body's abilities to repair.

The effects of LLLT on bone are still controversial as previous reports reveal conflicting results. It is possible that LLLT effect on bone regeneration depends not only on the total dose of irradiation, but also on the irradiation time and the irradiation mode (Continuous or Pulsed). Most importantly, a recent study has suggested that the threshold energy density and intensity are biologically independent from each other. This independence accounts for the success and the failure of LLLT achieved at low-energy density levels as described previously by Sommer et al [20]. This paper reports recent observations on the effect of LLLT on bone healing.

Materials and methods

We have evaluated morphometrically the amount of newly formed bone after 830nm laser irradiation of surgical wounds created in the femur of rats. Forty Wistar rats were divided into four groups of 12 animals each: group A (12 sessions, 4.8J/cm^2 per session, observation time of twenty-eight days); group C (three sessions, 4.8J/cm^2 per session, observation time of seven days). Groups B and D acted respectively as non-irradiated controls. Forty eight hours after the surgery, the defects of the experimental groups A and C were irradiated transcutaneously, with the hand piece perpendicularly positioned on the wound using a CW 40mW 830nm diode laser, (f~1mm) with a total dose of 4.8J/cm^2 (Laserbeam, Rio de Janeiro, Brazil). Irradiation was performed three times a week, resulting in a total of 12 applications (57.6J/cm^2) in Group A and three applications (14.4J/cm^2) in group C. The animals were humanely killed with an overdose of general anesthetics at the end of the experimental periods and specimens were taken. The specimens were routinely processed, embedded in wax, cut at 6mm thickness, and stained with H&E (Haematoxilyn and Eosin). Computerized morphometry was carried out using specific software (ImagelabÒ, São Paulo, Brazil). The best sets of images of each specimen from each group were selected for this analysis. The computerized system was calibrated in order to give a relationship of 1 pixel = 6.5mm. The area measured was delimited and quantified by the software (Fig.1).

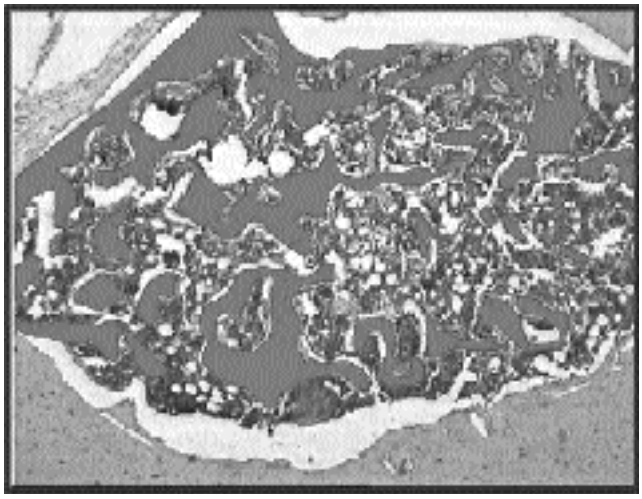

Figure 1: Delimitation of the area by the Imagelab

In a second investigation, we examined the effects of LLLT on bone healing after the insertion of implants. It is known that dental implants need four and six months period for fixation on the maxillae and on the mandible before receiving load. The literature revealed several reports on the effect of LLLT on the healing of soft tissue. One study assessed, clinically and with SEM, the efficacy of the use of 830nm (40mW) laser light with a dose of 4.8J/cm^2 on the healing of bone after the insertion of dental implants on the dog's tibiae. Ten male and female dogs with an average weight of 14Kg were used in this study and were divided into two groups. Each group had five animals that received the implant. Three animals were irradiated and two served as controls. The animals were sacrificed 45 and 60 days after surgery. The animals were irradiated three times a week for two weeks (contact mode) with a CW 40mW 830nm diode laser, (f ~1mm)

with a total dose per session of 4.8J/cm² and a dose per point of 1.2J/cm² (Laserbeam, Rio de Janeiro, Brazil). The animals were humanely killed with an intraperitoneal overdose of general anesthetics at the end of the experimental periods. After the removal, the specimens were routinely prepared for SEM (Scanning Electronic Microscopy).

Results

Histological aspect of irradiated and non-irradiated specimens at day seven and 28 can be seen in Figs. 2 and 3. Table 1 shows the comparison between the mean areas of irradiated and non-irradiated subjects. Fig. 4 shows the results of the measurements obtained for irradiated and non-irradiated specimens seven days after surgery. Mann-Whitney test showed a significant difference between irradiated and non-irradiated groups (p=0.017, Table 2) and within this experimental group (p=0.01, Table 3). On the other hand, Mann-Whitney test failed to demonstrate a significant difference between irradiated and non-irradiated defects 28 days after surgery (p=0.383, Table4). The results of the measurements can be seen on Fig. 5.

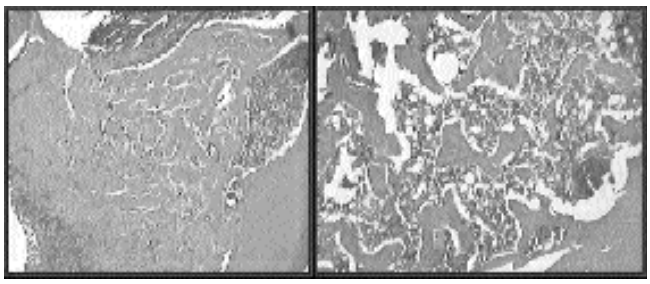

Figure 2: On the left, histological aspect of a non irradiated specimen seven days after surgery. On the right, at the same experimental time, the aspect of an irradiated specimen (H&E, x4).

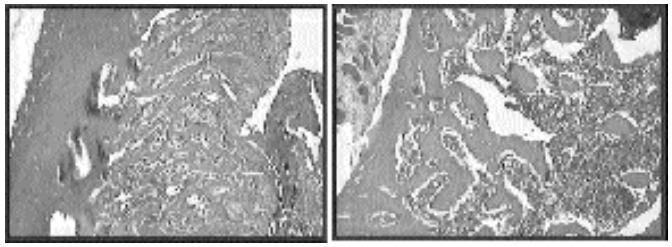

Figure 3: On the left, histological aspect of a non irradiated specimen 28 days after surgery. On the right, at the same experimental time, the aspect of an irradiated specimen (H&E, x4).

Table 1 - Comparison between the means of the areas on

Table 1 - Comparison between the means of the areas of irradiated and non-irradiated bone defects.

Group	*Time*	*Area*
Irradiated	07 days	2852629.12
	28 days	861794.15
Non-Irradiated	07 days	1561740.66
	28 days	655798.96

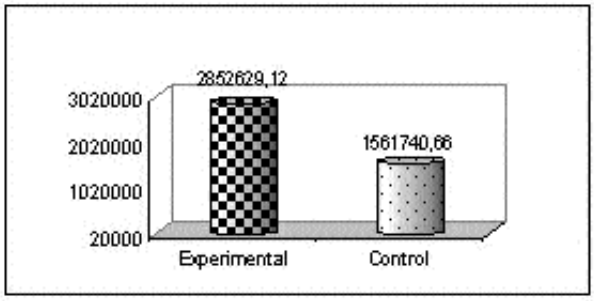

Fig.4: Comparison between the experimental and control groups at 7 days of healing.

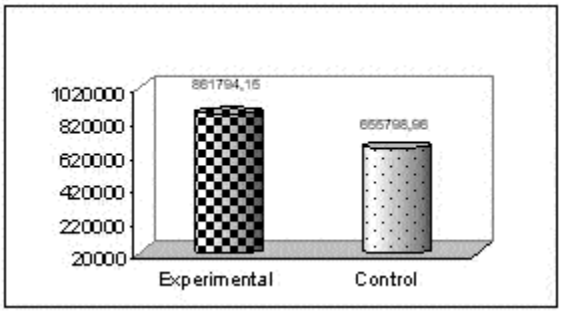

Fig.5: Comparison between the experimental and control groups at 28 days of repair.

Table 2 : Comparison between irradiated and non-irradiated samples seven days after surgery

Group	*Mean*	*SD*	*Variation Coefficient*	*P*
Irradiated	2852629.12	745985.83	26.15%	**0.017**
Non-Irradiated	1561740.66	248036.22	15.88%	

Table 3: Comparison between time and area of irradiated subjects; seven days verses 28 days.

Time	*Mean*	*SD*	*P*
7 days	2852629.12	745985.83	**0.01**
28 days	861794.15	470949.95	

Table 4 : Comparison between irradiated and non-irradiated samples 28 days after surgery.

Group	*Mean*	*SD*	*Variation Coefficient*	*p*
Experimental	861794.15	470949.95	54.61%	0.383
Control	655798.96	298272.25	45.50%	

On the second study, no macroscopic differences could be observed between irradiated and non-irradiated subjects throughout the experimental period. SEM analysis showed a better quality of the bone on both times on irradiated and non-irradiated specimens and can be seen on Figures 6-9.

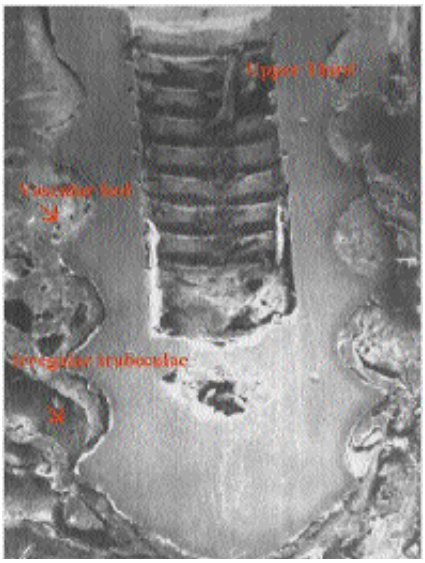

Fig 6: SEM of a nonirradiated specimen 45 days after implantation. Compact bone is observed on the upper third, presence of vascular beds. In the intermediate and lower thirds, it is observed irregular bone trabeculae limiting cavities (x12).

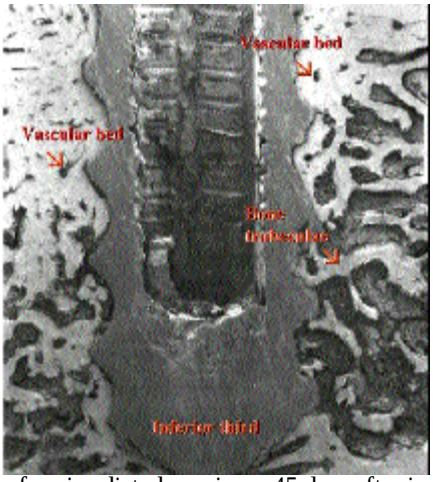

Fig 7: SEM of an irradiated specimen 45 days after implantation. There is a lamellar re-arrangement more pronounced at the bone/implant interface. Neovascularization is higher on the upper and intermediate thirds. There are also trabeculae on the lower third (x12).

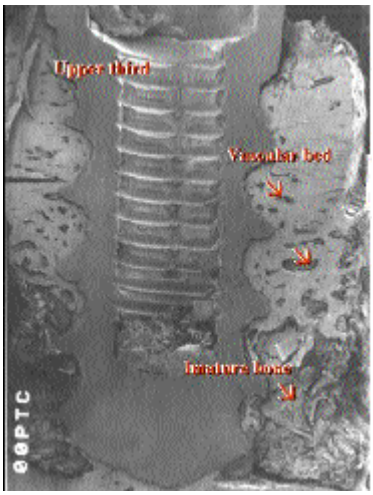

Fig 8: SEM of irradiated specimen 60 days after implantation. Presence of mature bone in the upper and intermediate thirds, good distribution of the vascular beds and lamellar arrangement of the bone at the implant/bone interface. In the lower third, the bone has a more immature aspect (x12).



Fig 9: SEM of non-irradiate specimen 60 days after implantation. The bone/implant interface shows an immature aspect (x100).

Discussion

The results of these studies reveal a better bone healing after irradiation with 830nm diode laser. Although LLLT effects on soft-tissue has been studied by several groups, there are a few works on the effect of LLLT on bone. Some previous reports do recognize that LLLT has positive effects on bone [18,19]. These studies reflect the idea that non-differentiated mesenchymal cells could be biomodulated positively to osteoblasts that would more rapidly change to osteocytes [18]. This aspect may be possibly corroborated by several previous studies in which LLLT was used in fractures [10], bone defects [26], tooth extraction [3,8,21] and after the placement of dental implants [13]. On the other hand, LLLT seems ineffective when used on normal tissues [19]. In order to observe the biomodulating effects of LLLT, some level of tissue deficiency seems necessary [14]. It is known that the osteogenic potential of mesenchymal cells depends on several genetic factors and also on systemic and local inducer factors [7]. LLLT may act as an inducer factor. However, some reports [23], suggested that LLLT would improve bone matrix production due to improved vascularization and anti-inflammatory effect. These aspects would increase both the release of mediators and micro-vascularization, which in turn would accelerate bone healing. It was suggested that PGE_2 activates wound healing [6], and increased level of PGE_2 was observed by Messer et al. [12]. There is evidence that PGE_2 is also produced by osteoblasts and that its effects may be therapeutic or adverse [25].

It is known that dental implants need four to six month period for fixation on the maxillae and on the mandible before receiving loading. Another point to be considered is that this kind of therapy may also be used in cases of fractures in which plates and screws are used for immobilization. The choice of IR laser light in these studies is due to its higher depth of penetration in tissues. The results observed by SEM are similar to previous reports, which demonstrated increased vascularization, quick alveolar socket repair and increased osteoblast, chrondrocyte and fibroblast activities [2,21,22,27]. In both studies low surface doses were kept in accordance with the findings of previous studies that suggested doses ranging from 1-4J/cm^2 [11]. Although some studies recommended higher doses, our clinical results on the use of LLLT suggest similar low doses [15,16] to the ones suggested in several studies within the range of 1-5J/cm^2 [19, 26,23]. In no case, did the session dose exceed 20J/cm^2. Exposure time and intensity in these studies are in accordance with the suggestion that stronger biomodulatory effects are observed at exposures timing ranging from 30 to 120s [24].

It is acknowledged that the controversy observed in the literature are due to different protocols used in which different wavelengths, association of wavelengths, different modes of emission and several doses were utilized in different animal or cell models. It is recognized that each method has its advantage and disadvantage. We tried to use reproducible methods of measurement, and visual analysis in the present investigations. It is also recognized that tissue morphology and the shape and distribution of the trabeculae may differ in the samples, leading to imprecise interpretation of the results found in these studies. However, we tried to use serial cuts in order to minimize variations in the reading. Approximately the same serial cut of each specimen was used for the computerized analysis or SEM. The computerized analysis was effective in measuring the area of newly formed bone and confirmed the findings of a previous report that also found increased bone proliferation after LLLT using a similar software and immunohistochemistry. This finding was not consistent with that of other research groups, which did not show positive effects of LLLT on healing bone [1,5]. Some previous reports, which found no biomodulating effects of LLLT [4], did not consider the systemic effect of LLLT [23,26]. They used the contra-lateral side of the same subject as controls. On the other hand, the findings of this investigation is very close to a study which found intense activity and high numbers of osteoblasts 5-6 days after the procedure was performed on bone defects in a similar model. Previous work using 790nm laser at a similar dose used in the present investigation, demonstrated a 10% increase on the amount of mineralized bone at seven days following irradiation. Another study examined bone consolidation, increased formation of trabecular bone, and the number of osteoblasts after the use of He-Ne laser (633nm, 1mW, f ~1.1mm). The experimental period was seven days and doses per treatment were 3.15, 31.5 and 94.7J/cm^2. Positive responses were found at 31.5 and 94.7J/cm^2 but not at lower doses. These values were higher than that used in this work. This may indicate a more effective effect of 830nm laser light in comparison to lasers emitting 632.8 or 790nm, since 830nm penetrates to a deeper level. It is concluded that the use of LLLT at 830nm significantly improves bone healing during the early stages. Further studies are needed on the effects LLLT on growth factors, BMPs, prostaglandin and bone forming genes.

Correspondence to:
Antonio L.B. Pinheiro
Professor of Oral and Maxillofacial Surgery
School of Dentistry
Department of Diagnostic and Therapeutics
Universidade Federal da Bahia
62 Araújo Pinho Ave

Canela, Salvador, BA, 40110-150, Brazil.
Phone: 55-71-99884140
email albp@ufba.br

REFERENCES

1. Anneroth G, Hall G, Ryden H, and Zetterquist L (1988): The effect of low-energy infrared laser radiation on wound healing in rats. Journal of Oral and Maxillofacial Surgery, 26:12 - 17.
2. Bisht D, Mehrotra, R, Singh, PA, Atri, SC, Kumar, A. (1994): Effect of low laser radiation on healing of open skin wounds in rats. Indian Journal Medical Research, 100:43 - 46.
3. Freitas AC (1998): Avaliação do efeito antiinflamatório do laser Diodo Infravermelho de 830nm através da monitorização da proteína C-Reativa. Recife: Universidade Federal de Pernambuco. 74pp.
4. Gordjestani M, Dermaut, M, and Thierens, H. (1994): Infrared laser and bone metabolism: A pilot study. International Journal of Oral and Maxillofacial Surgery, 23:54 - 56.
5. Hall G, Anneroth, G, Schennings, T, Zetterquist L, Ryden H (1994): Effect of low energy laser irradiation on wound healing. An experimental study in rats. Swedish Dental Journal, 18: 29 - 34.
6. Hight WB (1985) In: Trelles MA, and Mayayo E (1987): Bone fracture consolidates faster with low-power laser. Lasers in Surgery and Medicine, 7:36 - 45.
7. Katchburian E, and Arana-Chavez VE (1999): Histologia e Embriologia Oral: Texto-Atlas Correlações Clínicas. São Paulo: Panamericana. pp 41 - 70.
8. Kucerová H, Dostálová T, Himmlová L, Bártová J, and Mazánek J (2000): Low-level laser therapy after molar extraction. Journal of Clinical Laser in Medicine and Surgery, 18:309 - 315.
9. Lizarelli RFZ, Lamano-Carvalho TL, Brenttegnani LG (1999): Histometrical evaluation of the healing of the dental alveolus in rats after irradiation with a low-powered GaAlAs laser. In (Featherstone JDB, Rechman P, and Fried D, ed). Lasers Dentistry V, Billingham: SPIE. pp 49 - 56.
10. Luger EJ, Rochkind S, Wollman Y, and Kogan G (1998): Effect of low-power laser irradiation on the mechanical properties of bone fracture healing in rats. Lasers in Surgery and Medicine, 22: 97 - 102.
11. Mester E, Spiry, T, Szende, B, Tota, JG. (1971): Effect of laser rays on wound healing. American Journal of Surgery,122: 532 - 535.
12. Mester E, Mester AF, and Mester A (1985): The biomedical effects of laser application. Lasers in Surgery and Medicine, 5: 31 - 39.
13. Oliveira MAM (1999): Efeito da Radiação Laser Não Cirúrgica na Bioestimulação Óssea Pós-Implante: Ánálise com Microscopia Eletrônica de Varredura. Monografia de Especialização; Recife:Faculdade de Odontologia da Universidade Federal de Pernambuco. 88p
14. Pinheiro ALB, Nascimento SC, Vieira ALB, Rolim, AB, Silva, OS, Brugnera Jr, A, Zanin, FA. (2001): Effects of LLLT on malignant Cells: Study in Vitro. In (Rechman P, and Fried D,Haning P, ed). Lasers in Dentistry VII. Billingham: SPIE. pp 56 - 60.
15. Pinheiro, ALB, Cavalcanti, ET, Pinheiro, TITNR, Alves, MJPC, Miranda, ER. (1997): Low-level laser therapy in management of disorders of the maxillofacial region. Journal of Clinical Laser in Medicine and Surgery, 15: 81 - 183.
16. Pinheiro ALB, Cavalcanti, ET, Pinheiro, TITNR. (1997): LILT in the treatment of disorders of the maxillofacial region. In (Wigdor HA, Featherstone JDB, and Rechman P, eds). Lasers in Dentistry III. Bellingham: SPIE. pp 227-234.
17. Pinheiro ALB (1993): Comparison of tissue damage and healing in scalpel and CO2 Laser mucosal wounds. Birmingham: University of Birmingham, PhD Thesis, 529 p.
18. Pinheiro ALP, and Frame JF (1992): Laser em Odontologia: Seu Uso Atual e Perspectivas Futuras. Revista Gaucha de Odontologia. 40: 327 - 332.
19. Saito S, and Shimizu N (1997): Stimulatory effects of low-power laser irradiation on bone regeneration in midpalatal suture during expansion in the rat. American Journal of Orthodontics & Dentofacial Orthopedics, 111:525 - 532.
20. Sommer AP, Pinheiro ALB, Mester A, Franke RP, and Whelan, HT (2001): Biostimulatory windows in low intensity laser activation: Lasers, Scanners and NASA's Light Emitting Diode Array System. Journal Clinical Laser Medicine and Surgery,19:29 - 34.
21. Takeda Y (1988): Irradiation effect of Low-energy laser on alveolar bone after tooth extraction: Experimental study in rats. International Journal of Oral Maxillofacial Surgery, 7:388 - 391.
22. Tang XM, and Chai BP (1986): Effect of C02 laser irradiation on experimental fracture healing: a transmission electron microscopic study. Lasers in Surgery and Medicine, 6:346 - 352.
23. Trelles MA, and Mayayo E (1987): Bone fracture consolidates faster with low-power laser. Lasers in Surgery and Medicine, 7:36 - 45.
24. Tunér J, and Hode L (1999): Low level laser therapy (Clinical Practice and Scientific Background). Gängesberg: Prima Books. 404p.
25. Valcanaia TC (1999): A influência do uso do antiinflamatório não hormonal, o diclofenaco potássico, no

reparo ósseo. Tese de Doutorado. Porto Alegre: Pontifícia Universidade Católica do Rio Grande do Sul. 99p.
26. Yaakobi T, Maltz L, and Oron U (1996): Promotion of bone repair in the cortical of the tibia in rats by low energy laser (He-Ne) irradiation. Calcified Tissue International. 59:297 - 300.
27. Yamada K (1991): Biological effect of low power laser on clonal osteoblastic cells (MC3T3-E1). Nippon Seikeigeka Gakkai Zasshi, pp 787-799.

Join the World

Join The World Association for Laser Therapy

How To Join

(1) Wire transfer your journal subscription and membership fee directly to Kansas Corporate Credit Union, Wichita, Kansas (routing number 301180111). To ensure proper credit, you must instruct Kansas Corporate Credit Union as follows: "Please further credit KUMC Credit Union (account ABA: 301078731) for deposit in Walt '98 account number 30475".

OR

(2) Send a countersigned Traveler's Check or an international bank draft (made payable to WALT) to the Editor-in-Chief or the Business Manager (see address in this issue of the journal).

OR

(3) Pay by credit card at our Website: [www.walt.nu].