

THERMOGRAPHIC STUDY OF LOW LEVEL LASER THERAPY FOR ACUTE-PHASE INJURY

Yoshimi Asagai, M.D.¹, Atsuhiro Imakiire, M.D.², Toshio Ohshiro, M.D.³,

1. Shinano Handicapped Children's Hospital Shimosuwa, Nagano, Japan

2. Department of Orthopaedic Surgery, Tokyo Medical University Shinjuku, Tokyo, Japan

3. Japan Medical Laser Laboratory, Shinanomachi, Tokyo, Japan

Acute-phase injury is generally treated by localized cooling of the region, and rarely by the active use of low level laser therapy (LLLT) in Japan. Thermographic studies of acute-phase injury revealed that circulatory disturbances at the site of trauma occurred due to swelling and edema on the day following the injury, and that skin temperature was high at the site of the trauma and low at the periphery. Following LLLT, circulatory disturbances rapidly improved, while temperature in the high temperature zone around the site of trauma fell by 3 degrees on the average, but at the periphery the low temperature rose by 3 degrees on the average to nearly normal skin temperature. Clinically, swelling and edema improved. LLLT was also useful in treating necrosis of the skin in the wound area and in accelerating healing of surgical wounds of paralytic feet, which are prone to delayed, wound healing and also wounds due to spoke injury. LLLT is useful in treating swelling and edema in acute-phase injury and in accelerating healing of surgical wounds.

Key words: Laser therapy, acute-phase injury, thermography, ankle joint sprain

Introduction

It has not been clearly defined to date if LLLT is indicated for acute-phase injury with swelling and calor. Yet it is frequently considered to be contraindicated in acute-phase injury.

We have previously reported that, in patients with cerebral palsy with reduced peripheral skin temperature, the skin surface temperature was elevated to normal after LLLT (1). In this study, we used thermography to examine changes in skin temperature following LLLT chiefly in acute-phase injury.

Patients and Methods

Subjects were 7 patients with sprains of the ankle joint, two patients with fractures of the tibial shaft, and one patient with dislocation of the elbow joint. LLLT was also used in orthopedic surgery for disorders of the distal lower extremity such as talipes varus, which is frequently followed by postoperative necrosis of the skin in the wound area as well as delayed wound healing, and pre- and post-operative treatment of paralytic feet with circulatory disturbances. The procedure was as follows. Room temperature was maintained at 25°C. After acclimatization for 20 minutes, continuous irradiation with a GaAlAs semiconductor laser (JQ305, Minato Medical Science Co., Ltd., Japan) with the wavelength adjusted to 810 nm and the output to 100mW was applied using the contact method. The spot size on the tissue was 0.56cm² with a power density of 17.86W/cm² at 100mW, the energy density per point being 107.5J/cm². The area surrounding the site of

trauma was irradiated for 3 to 5 minutes in total, one minute per spot, and changes in the skin surface temperature were followed using Thermotracer TH1106.

The test was performed from immediately after injury till 5 days post-trauma, an average of two days after injury.

Results

Immediately after injury, the skin surface temperature was elevated to about 34 degrees at and around the site of trauma (Fig. 1). On the day following the injury, skin temperature remained elevated around the site of trauma to the same degree as immediately after injury, but was markedly reduced to about 29 degrees at its periphery (Fig. 2). Skin temperature began to fall in the high temperature zone and began to rise in the peripheral low temperature zone immediately following LLLT, and the peripheral skin temperature reached a peak or became almost normal at about 40 minutes after the initiation of irradiation (Fig. 3). Changes in post-LLLT skin temperature in all patients

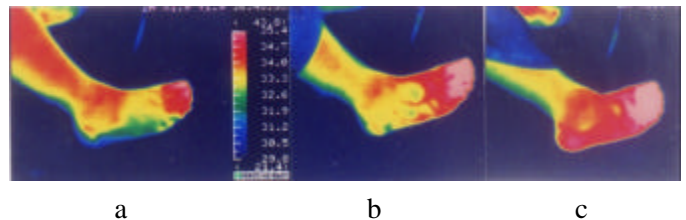


Fig. 1. Sprain of the right ankle joint immediately after injury: a) Before irradiation, a high temperature zone extends over the trauma site and a wide area around it. b) At 10 minutes after LLLT, skin temperature fell at the trauma site, and rose in the toes at the periphery. c) At 20 minutes after LLLT, skin temperature was re-elevated at the trauma site.

showed that skin temperature fell by an average of 3 degrees in the high temperature zone around the site of trauma, and rose by an average of 3 degrees in the peripheral low temperature zone, both to approximately normal skin temperature. Clinically, swelling and edema were diminished, and repeated irradiation suppressed exacerbation of swelling and edema.

Patients receiving pre- and post-operative application of

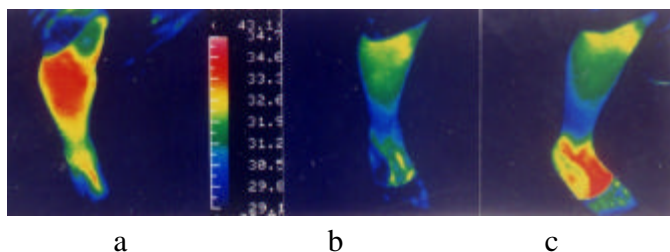


Fig. 2. Contusion of the right tibial shaft 1 day after injury: a) Before irradiation, skin temperature is high at the trauma site, and low at the periphery. b) At 10 minutes after LLLT: skin temperature fell at the trauma site, and rose slightly at the periphery. c) At 40 minutes after LLLT: skin temperature at the periphery reached a peak and nearly normal skin temperature.

LLLT for such conditions as talipes varus, in which post-operative necrosis of skin in the wound area and delayed wound healing are frequent, spoke injury produced when the foot is caught in a bicycle's spokes (Fig. 4), and paralytic feet with distal circulatory failure due to spina bifida or cerebral palsy, we have not seen any necrosis of the skin in the wound area or delayed wound healing.

Discussion

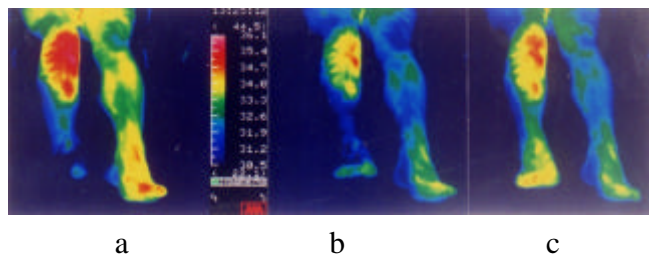


Fig. 3. Fracture of the right tibia 2 days after removal of nailing: a) Before irradiation, skin temperature was high in the surgical wound, and low at the periphery. b) Immediately after LLLT, skin temperature was reduced in the high temperature zone, and elevated in the low temperature zone. c) At 40 minutes after LLLT, skin temperature at the periphery reached a peak.

There have been many reports on wound healing (2, 3). Currently, the site of trauma is cooled to reduce swelling in acute-phase injury. An important problem in the healing of wounds and associated fractures is how to suppress swelling and edema, and improvement of local swelling and edema is also crucial for the healing of ligament injury in sprained ankles. However, the use of LLLT for sprained ankles is controversial (4). Thermography has been used for evaluating the effect of LLLT (5). In the present thermographic evaluation, the surface temperature was high around the trauma site and low in the periphery,

which indicated that local blood and lymph flow were impaired by swelling and edema, thus raising temperature. When LLLT was applied to these areas, it was found that skin temperature fell in the high temperature zone but rose in the low temperature zone to approximately the normal temperature in both zones, suggesting improved blood and lymphatic circulation.

Clinically, reduction of local swelling and edema was considered to have led to the improvement of blood and lymph flow.

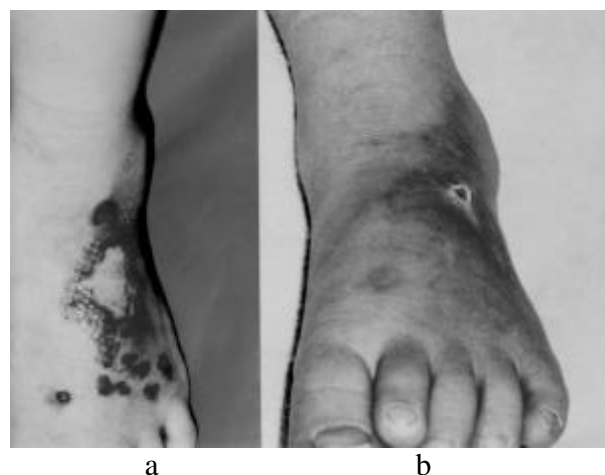

Fig. 4. Spoke injury: a) At 6 days after injury the left foot had been caught in the rear wheel of a bicycle, and this left a large skin defect on the back of the foot and a contusion, with marked swelling and edema. b) After daily LLLT, epithelialization was observed and the wound healed at 23 days after injury.

Conclusions

- 1: In acute-phase injury, skin temperature was elevated around the site of trauma, and reduced in the periphery on the day following the injury.
- 2: Immediately after irradiation, skin temperature fell by 3°C on the average in the high temperature zone around the trauma site, and rose by 3°C on the average reaching normal temperature in the low temperature zone at the periphery of the injury.
- 3: LLLT rapidly improved blood and lymphatic flow, which had been impaired by injury, and alleviated swelling and edema. LLLT was also useful in accelerating healing of the surgical wound.

Address for Correspondence:

Yoshimi Asagai MD, Director, Shinano Handicapped Children's Hospital, 6525-1 Shimosuwa, Suwagun, Nagano, Japan 393

Tel: +81-266 -27 -8414

Fax : +81- 266 -27- 7936

Email: Asagai@poplar.ocn.ne.jp

References

1. Asagai, Y., Ueno, R., Miura, Y., Ohshiro, T. (1995): Application of low reactive-level laser therapy (LLLT) in patients with cerebral palsy of the adult tension athetosis type. *Laser Therapy*, 7:113-118.
2. asaki, K., Ohshiro, T. (1997): Assessment in the rat model of the effects of 830nm diode laser irradiation in a diachronic wound healing study. *Laser Therapy*, 9:25-32.
3. ubota, J., Ohshiro, T. (1996): The effects of diode laser LLLT on flap survival: Measurement of flap microcirculation with laser speckle flowmetry. *Laser Therapy*, 8:241-246.
4. Robert A. Henrica C.W., Ton F, Lenssen, Frans, A.J.M., Gauke, K., Paul G. (1998): Low-level laser therapy in ankle sprains: A randomized clinical trial. *Arch. Phys. Med. Rehabil*, 79:1415-1420.
5. Ohshiro, T. (1988): Thermographic analysis and evaluation of pain attenuation with the GaAlAs LLLT laser system. In Ohshiro T and Calderhead RG: 'Low Level Laser Therapy: A Practical Introduction'. John Wiley & Sons, Chichester, UK. pp.56-62.

Join The World Association for Laser Therapy (WALT)



Leaders of International laser organizations met during the third Congress of the World Association for Laser Therapy held in Athens, Greece, to explore ways of advancing research, education and practice world-wide. Photo was taken immediately after the special session in May, 2000

<http://www.walt.nu>